

## Articular disease of the hand - the target joint approach

**Poster No.:** C-1817  
**Congress:** ECR 2016  
**Type:** Educational Exhibit  
**Authors:** R. R. Domingues Madaleno<sup>1</sup>, A. P. Pissarra<sup>1</sup>, I. Abreu<sup>2</sup>, A. Canelas<sup>1</sup>, L. Curvo Semedo<sup>1</sup>, F. Caseiro Alves<sup>1</sup>; <sup>1</sup>Coimbra/PT, <sup>2</sup>Porto/PT  
**Keywords:** Diagnostic procedure, Education, Conventional radiography, Musculoskeletal joint, Extremities, Bones, Arthritides  
**DOI:** 10.1594/ecr2016/C-1817

Any information contained in this pdf file is automatically generated from digital material submitted to EPOS by third parties in the form of scientific presentations. References to any names, marks, products, or services of third parties or hypertext links to third-party sites or information are provided solely as a convenience to you and do not in any way constitute or imply ECR's endorsement, sponsorship or recommendation of the third party, information, product or service. ECR is not responsible for the content of these pages and does not make any representations regarding the content or accuracy of material in this file.

As per copyright regulations, any unauthorised use of the material or parts thereof as well as commercial reproduction or multiple distribution by any traditional or electronically based reproduction/publication method is strictly prohibited.

You agree to defend, indemnify, and hold ECR harmless from and against any and all claims, damages, costs, and expenses, including attorneys' fees, arising from or related to your use of these pages.

Please note: Links to movies, ppt slideshows and any other multimedia files are not available in the pdf version of presentations.

[www.myESR.org](http://www.myESR.org)

# Learning objectives

To provide an insight on the articular diseases of the hand on conventional radiography.

To schematically illustrate the articular distribution pattern of radiographic findings in several pathologic conditions affecting the hands.

## Background

Even though MRI provides greater accuracy in the diagnosis of articular diseases of the hand, conventional radiology still is the first line imaging modality for the evaluation of hand arthropathy.

According to Manaster et al, the radiographic assessment of arthritis comprises the evaluation of the articular alignment, bone density and new bone formation, cartilage destruction, distribution of affected joints, presence of erosions and soft tissue involvement.

The arthritides have a preferential joint involvement (Fig. 1), and a preferential region within the joint. They can be monoarticular when they involve one joint, oligoarticular, when they affect just a few joints, or polyarticular when multiple joints are involved. They can also be distinguished by their symmetry or asymmetry.

Further, arthritides are well characterized by evaluating their effect in the hands joints.

The pattern of distribution in the hands is divided into three categories that we will discuss below (Fig. 2).

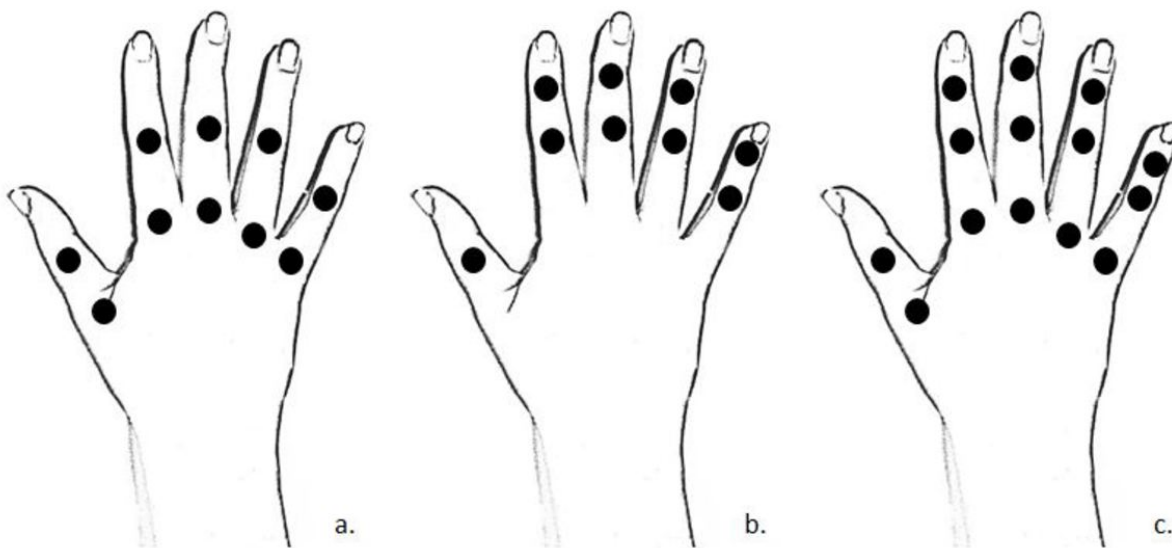
**Images for this section:**

<b>Diseases that preferentially affect the proximal joint</b>	Rheumatoid arthritis Juvenile chronic arthritis Systemic lupus erythematosus Calcium pyrophosphate dihydrate crystal deposition disease
<b>Diseases that preferentially affect the distal joints</b>	Psoriatic arthritis Erosive osteoarthritis Scleroderma and polymyositis
<b>Diseases that affect all the hand joints</b>	Ankylosing spondylitis Degenerative joint disease Gouty arthritis

Table 1. Arthritis pattern of distribution.

**Fig. 1:** Arthritis pattern of distribution

© Radiology Department, Coimbra University Hospital - Coimbra/PT



**Fig. 2:** Arthritis pattern of distribution. a. Proximal joints. b. Distal joints. c. All the hand joints.

© Radiology Department, Coimbra University Hospital - Coimbra/PT

## Findings and procedure details

In the hand, the pattern of distribution is divided into three categories that will be discussed below.

### DISEASES THAT PREFERENTIALLY AFFECT THE PROXIMAL JOINTS

#### RHEUMATOID ARTHRITIS

Rheumatoid arthritis (RA) is a multisystemic disease that has a slight prevalence in the male. Usually the articular symptoms predominate, affecting both the axial and appendicular skeleton, with a polyarticular and symmetric pattern. In the hand and wrist, proximal disease is the classical presentation of RA. Early erosion in the metacarpophalangeal (MCP) joint followed by the proximal interphalangeal (PIP) involvement is typical (Fig.3). Changes in distal interphalangeal (DIP) are less frequent in the early stage of the disease, and often only occur when there is a diffuse RA. Leading radiological findings in early disease usually are seen in the second and third MCP joints and the third PIP joint.

With the tendons rupture, there are certain deformities that became common, like swan neck deformity, with PIP hyperextension and DIP hyperflexion, boutonnière deformity, with PIP hyperflexion and DIP hyperextension and Hitchhiker's thumb where the MCP are flexed and the IP are in extension (Fig. 4).

#### JUVENILE CHRONIC ARTHRITIS

Juvenile chronic arthritis is a group of disease of unknown origin. The disease can be symmetrical or asymmetrical, and the distribution polyarticular, or, most commonly oligoarticular. Although this condition mostly involve the large joints, this arthritis can affect the hand and the wrist in a distribution similar to the one of rheumatoid arthritis, involving specially the MCP and the PIP joints (Fig. 5 and Fig. 6). Nevertheless, the ankylosis and periarticular osteopenia are usually a feature but erosions are only seen in late stages.

#### SYSTEMIC LUPUS ERYTHEMATOSUS

Systemic lupus erythematosus is a multisystemic autoimmune disease with afroamerican female prevalence. SLE is a bilateral and symmetrical nonerosive polyarthrite that usually affects hand and wrist joints. It has a proximal distribution, affecting metacarpophalangeal and proximal interphalangeal joints (Fig. 7). The joints can show some deformities, usually reversible, namely ulnar subluxation of the

metacarpophalangeal joints (Fig. 8). This autoimmune disease typically has a high incidence of osteonecrosis.

### CALCIUM PYROPHOSPHATE DIHYDRATE CRYSTAL DEPOSITION DISEASE

Calcium pyrophosphate dihydrate crystal deposition disease results in intra-articular and para-articular CPPD crystal deposition and it doesn't have gender predominance. This disease has a bilateral and symmetrical distribution. In the hand the most frequently involved joints are the second and third metacarpophalangeal joints, with interphalangeal joints appearing spared (Fig. 9 and Fig. 10).

## **DISEASES THAT PREFERENTIALLY AFFECT THE DISTAL JOINTS**

### PSORIATIC ARTHRITIS

Psoriatic arthritis is a symmetric arthropathy, mixing erosive and bone productive changes. It doesn't have gender predominance and generally affects young adults. It has five patterns, namely oligoarthritis, polyarthritis, symmetric type, arthritis mutilans and spondyloarthropathy. Early erosive disease in the distal interphalangeal joints is a typical manifestation, however proximal interphalangeal joints and, less frequently, metacarpophalangeal joints can be involved (Fig. 11 and Fig. 12). These abnormalities can progress to a pencil-in-cup deformity. The disease can also have a raylike distribution with one or two digits involved.

### EROSIVE OSTEOARTHRITIS

Erosive osteoarthritis is an osteoarthritis variant with female prevalence. Most frequently affects the distal and proximal interphalangeal joints, in a bilateral and symmetrical or asymmetrical distribution (Fig. 13 and Fig. 14). This disease combines central erosive and marginal productive bone changes, which result in typical "gull-wing" appearance.

### SCLERODERMA AND POLYMYOSITIS

Scleroderma and polymyositis are autoimmune diseases with female prevalence. These diseases have an erosion bilateral pattern, however arthritis is not a common finding, particularly in polymyositis. They affect the distal interphalangeal joints, and less frequently, the PIP joints (Fig. 15 and Fig. 16). Soft tissue changes are much more common. In scleroderma, soft tissue calcifications, progressive distal phalanges tapering and acro-osteolysis are typical. In polymyositis one can also find soft tissue calcification and fatty atrophy, mainly in the late stage.

## **DISEASES THAT AFFECT ALL THE HAND JOINTS**

### **ANKYLOSING SPONDYLITIS**

Ankylosing spondylitis is a seronegative spondyloarthropathy of unknown origin that has a male preference. It has a predilection for axial skeleton and large proximal appendicular joints with an erosive and osseous productive pattern. The hands are less frequently involved and all the hand joints can be affected (Fig. 17). Ankylosing spondylitis has a bilateral distribution, showing initially an asymmetrical joint involvement that can become symmetrical.

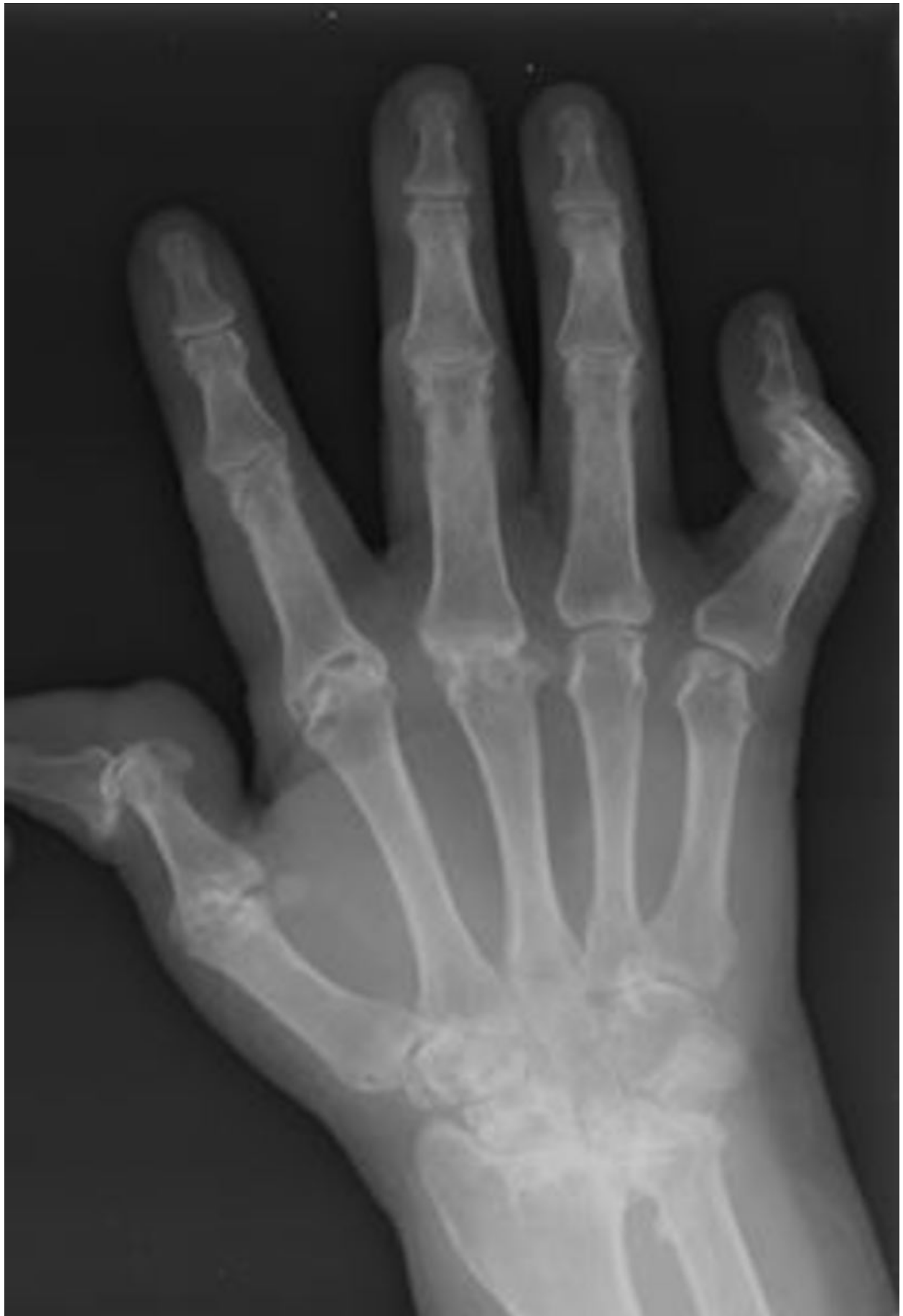### **DEGENERATIVE JOINT DISEASE AND INFLAMMATORY OSTEOARTHRITIS**

Degenerative joint disease or osteoarthritis and inflammatory osteoarthritis are a productive arthritis that have similar findings. Hands osteoarthritis is related to the primary OA that is due to a genetic defect in cartilage synthesis. These diseases are characterized by nonuniform articular narrow, subchondral sclerosis and osteophyte formation, in a bilateral and symmetric or asymmetric distribution. It affects PIP and DIP joints with marginal erosion and, less often, the MCP joints, usually showing an osteophyte formation (Fig. 18 and Fig. 19). Typically, the MCP are not involved singly. Inflammatory OA can be distinguish by central erosion and soft tissue swelling.

### **GOUTY ARTHRITIS**

Gouty arthritis is related to sodium urate crystal-induced deposition disorder with crystals deposition in articular and periarticular tissues and in subchondral bone. The gout has male predominance. Monoarticular or oligoarticular arthritis is typical, with overhanging edges of intra or para-articular erosions, articular space conservation and absence of osteoporosis. It preferentially affects small joints of lower extremities in a bilateral and asymmetric distribution. In hands, it involves PIP and DIP, and more rarely the MCP (Fig. 20 and Fig. 21).

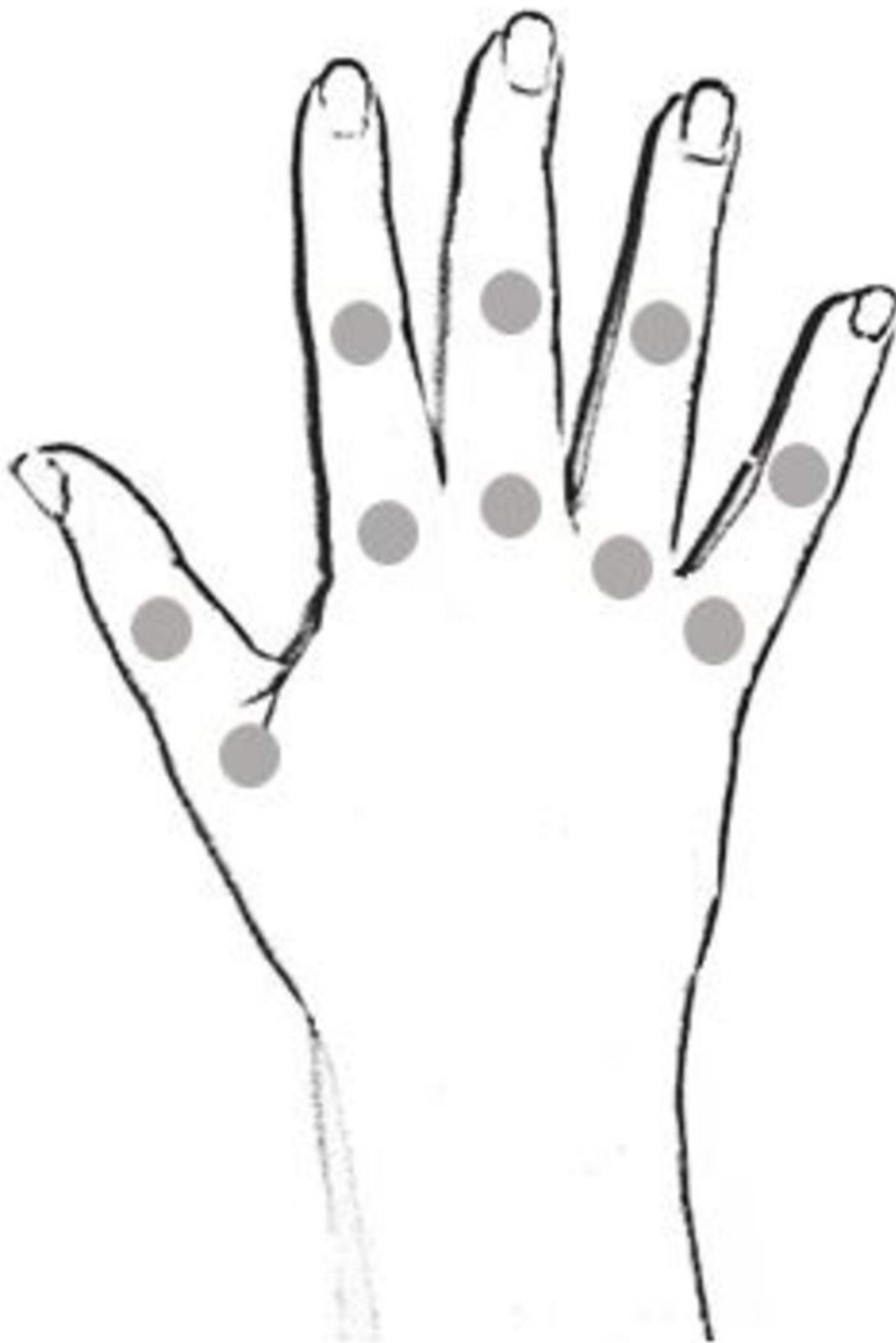
**Images for this section:**



**Fig. 4:** Rheumatoid arthritis. PA radiographic view with changes in MCP and PIP, boutonnière deformity of the fifth finger and Hitchhiker's thumb.

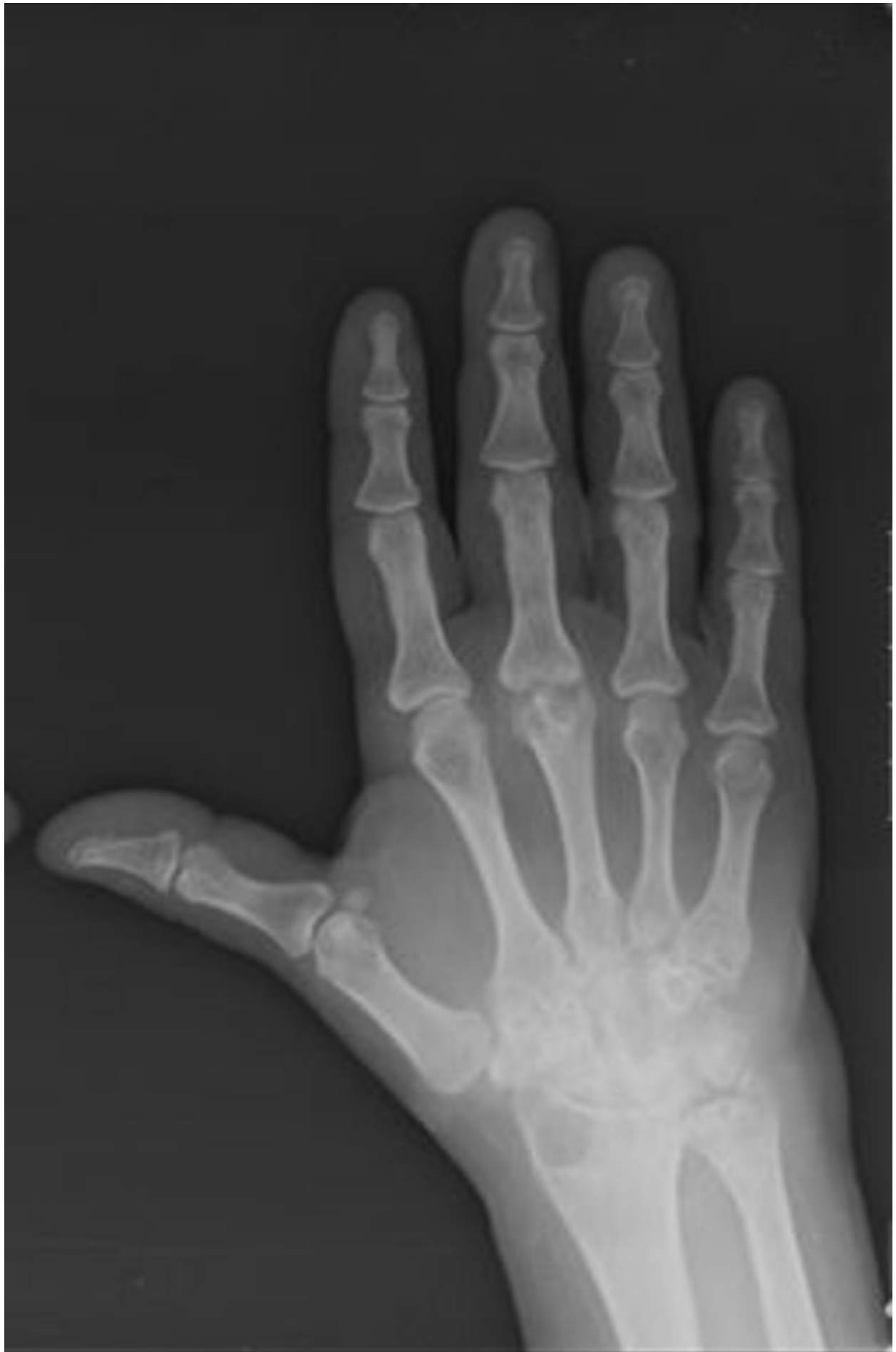© Radiology Department, Coimbra University Hospital - Coimbra/PT





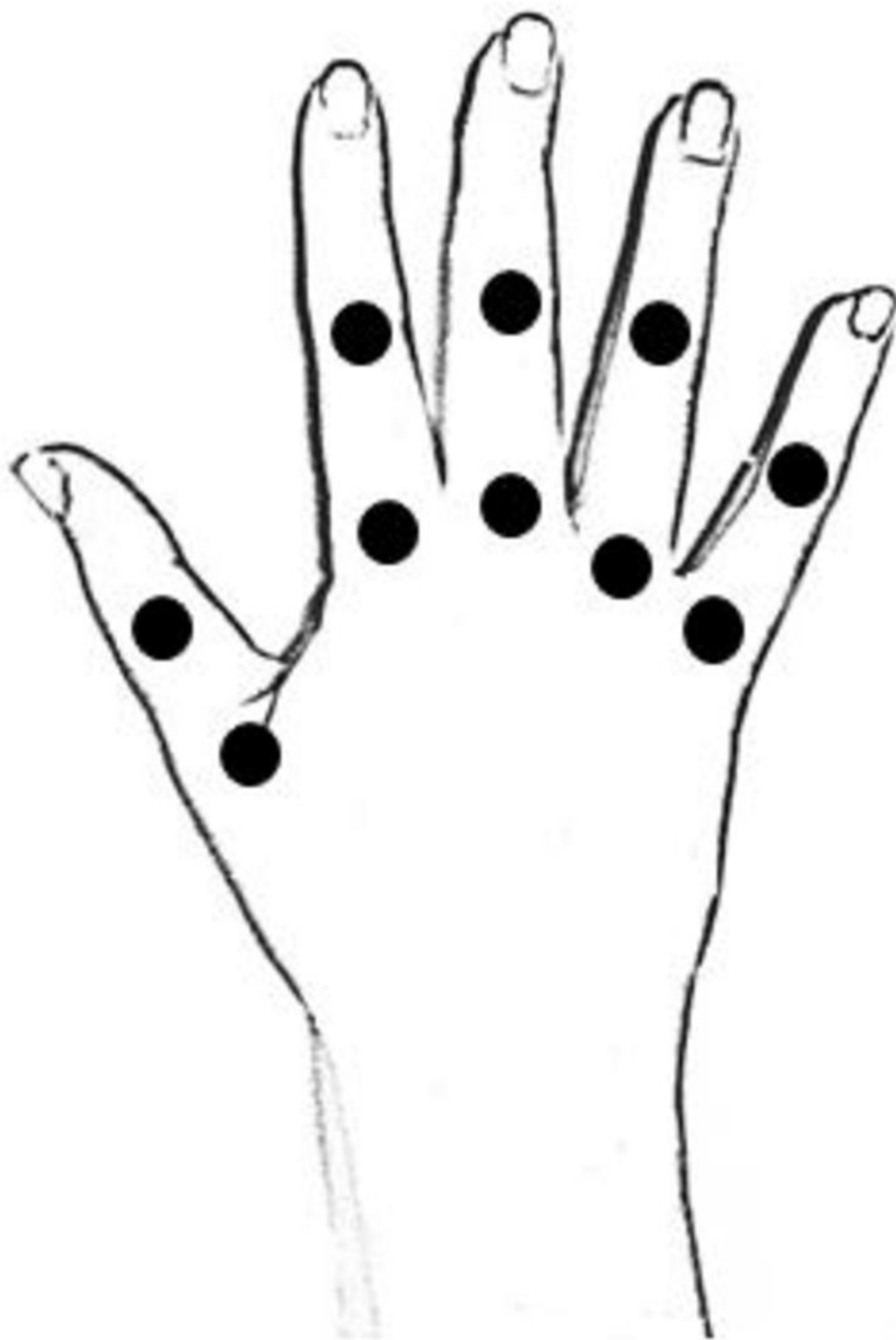**Fig. 5:** Juvenile chronic arthritis. Scheme of involved joints.

© Radiology Department, Coimbra University Hospital - Coimbra/PT



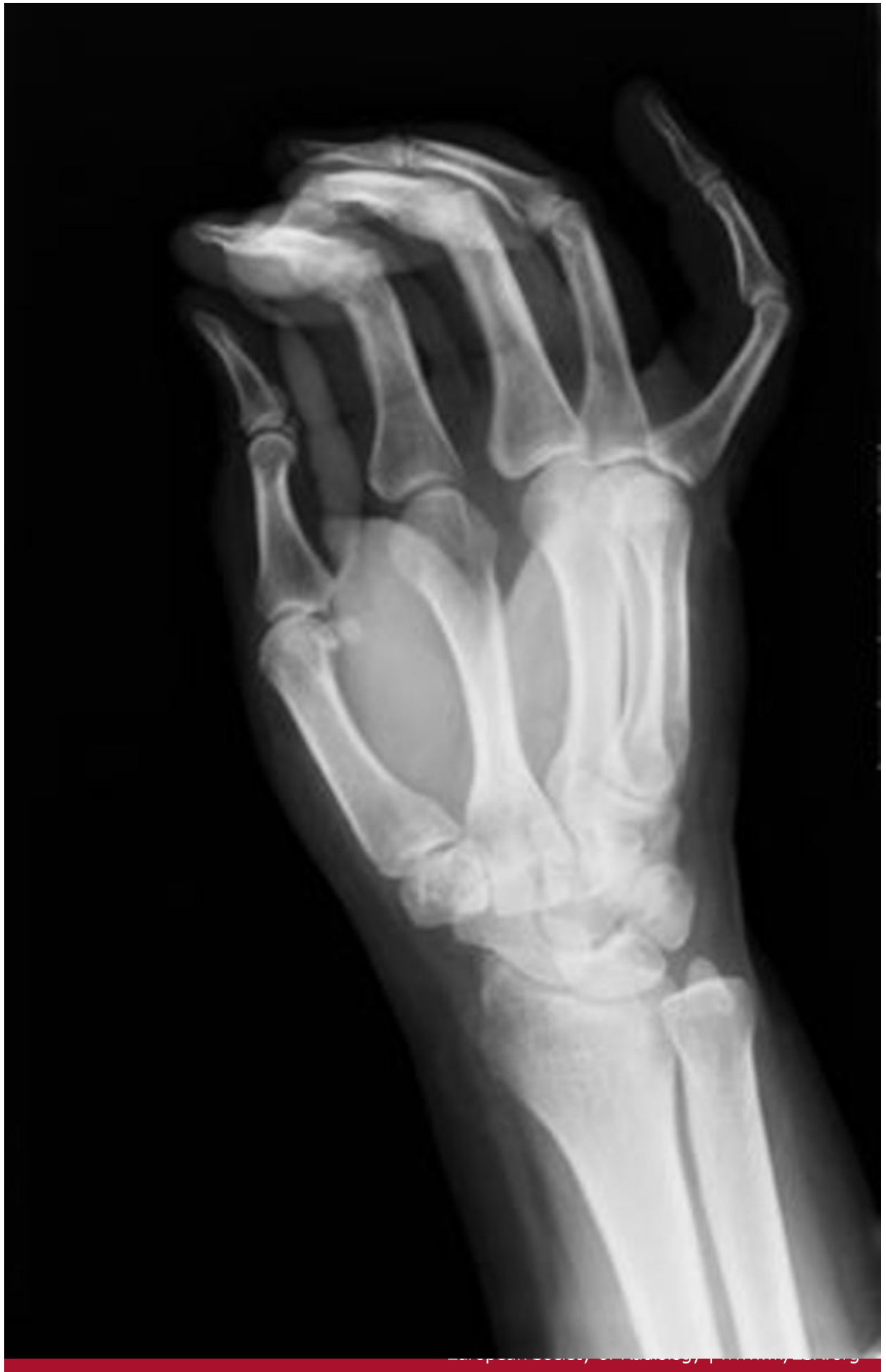**Fig. 6:** Juvenile chronic arthritis. PA radiographic view with changes in third MCP joint.

© Radiology Department, Coimbra University Hospital - Coimbra/PT



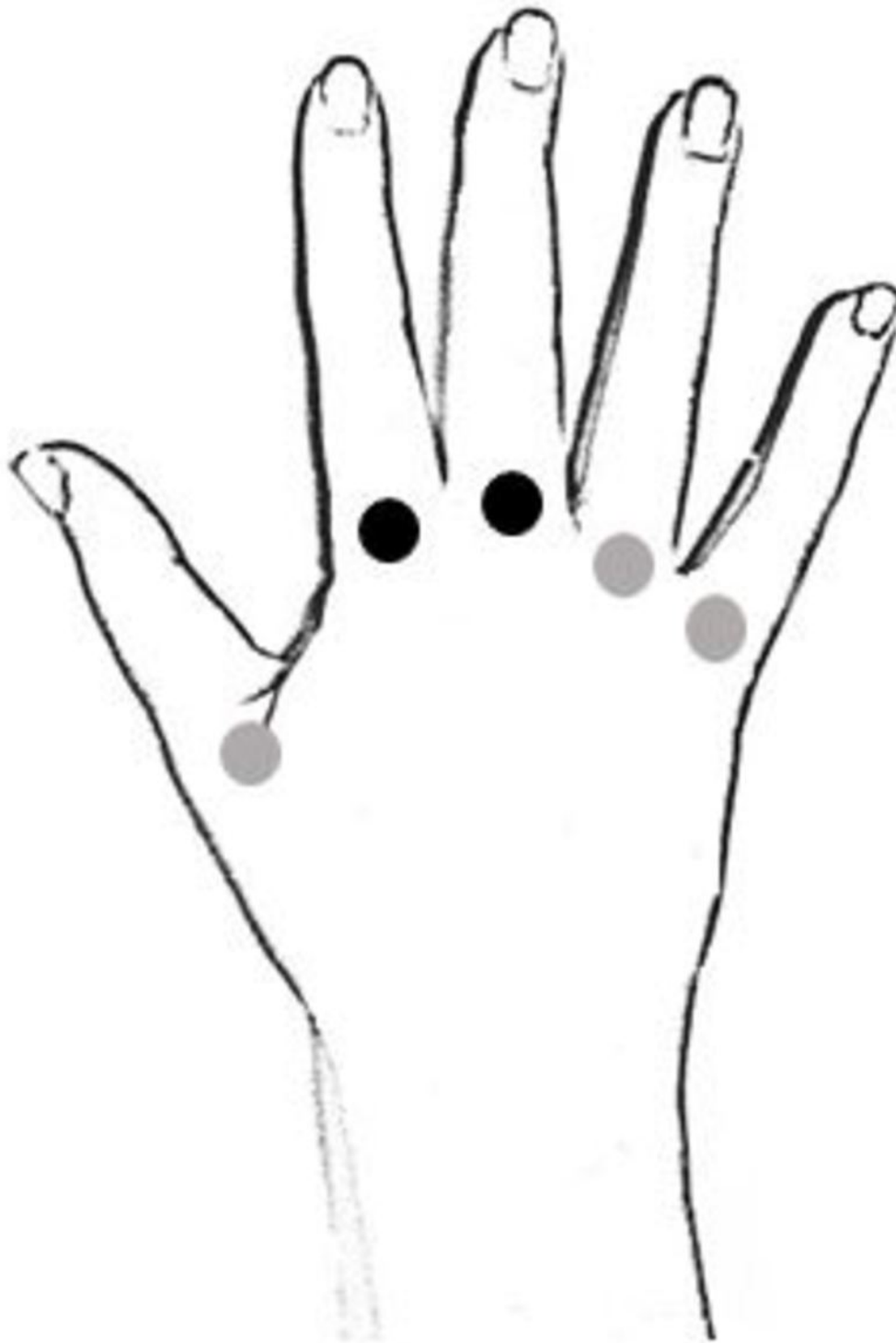
**Fig. 7:** Systemic lupus erythematosus. Scheme of involved joints.

© Radiology Department, Coimbra University Hospital - Coimbra/PT



**Fig. 8:** Systemic lupus erythematosus. Lateral hand view with deformities in fifth finger.

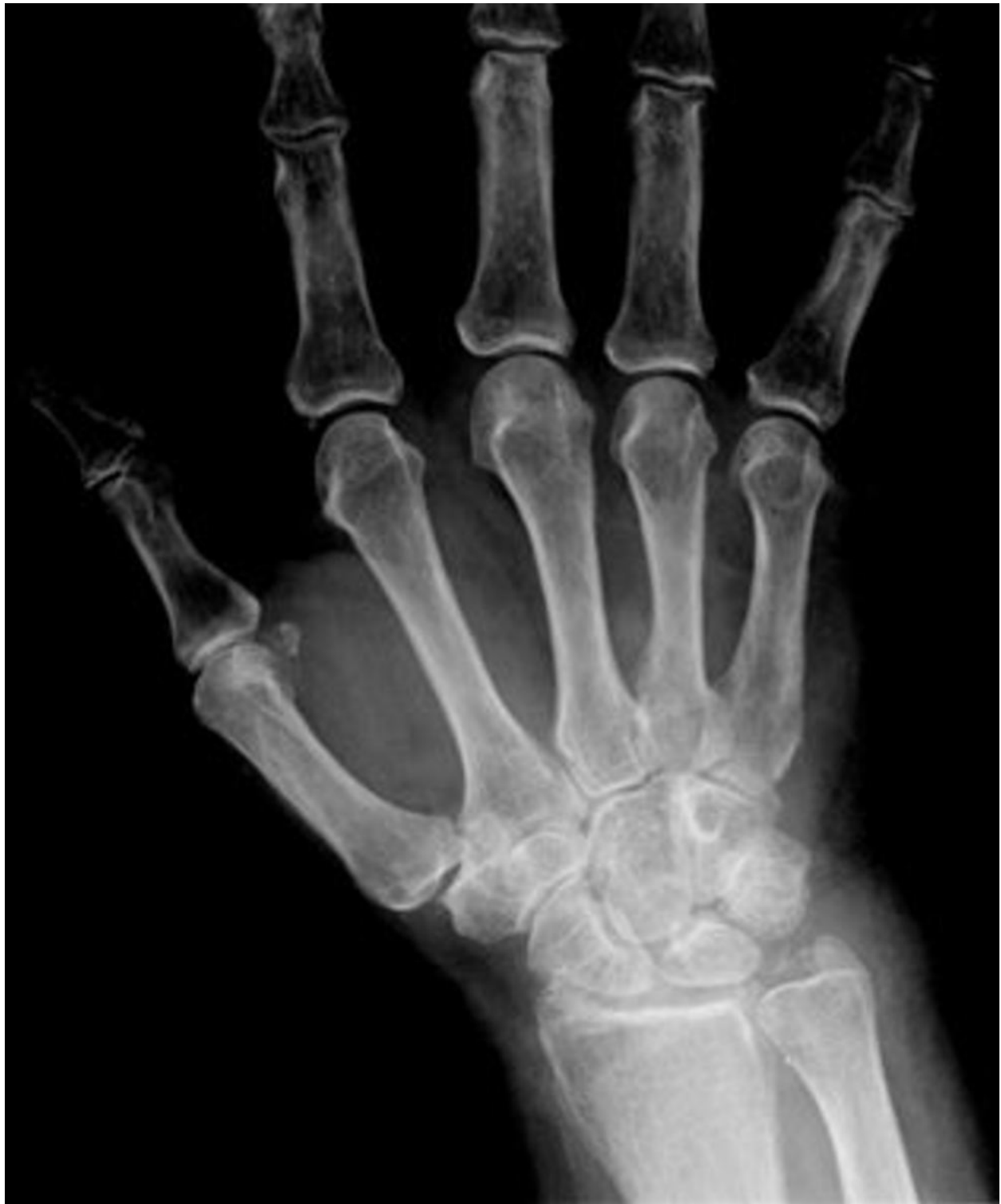© Radiology Department, Coimbra University Hospital - Coimbra/PT





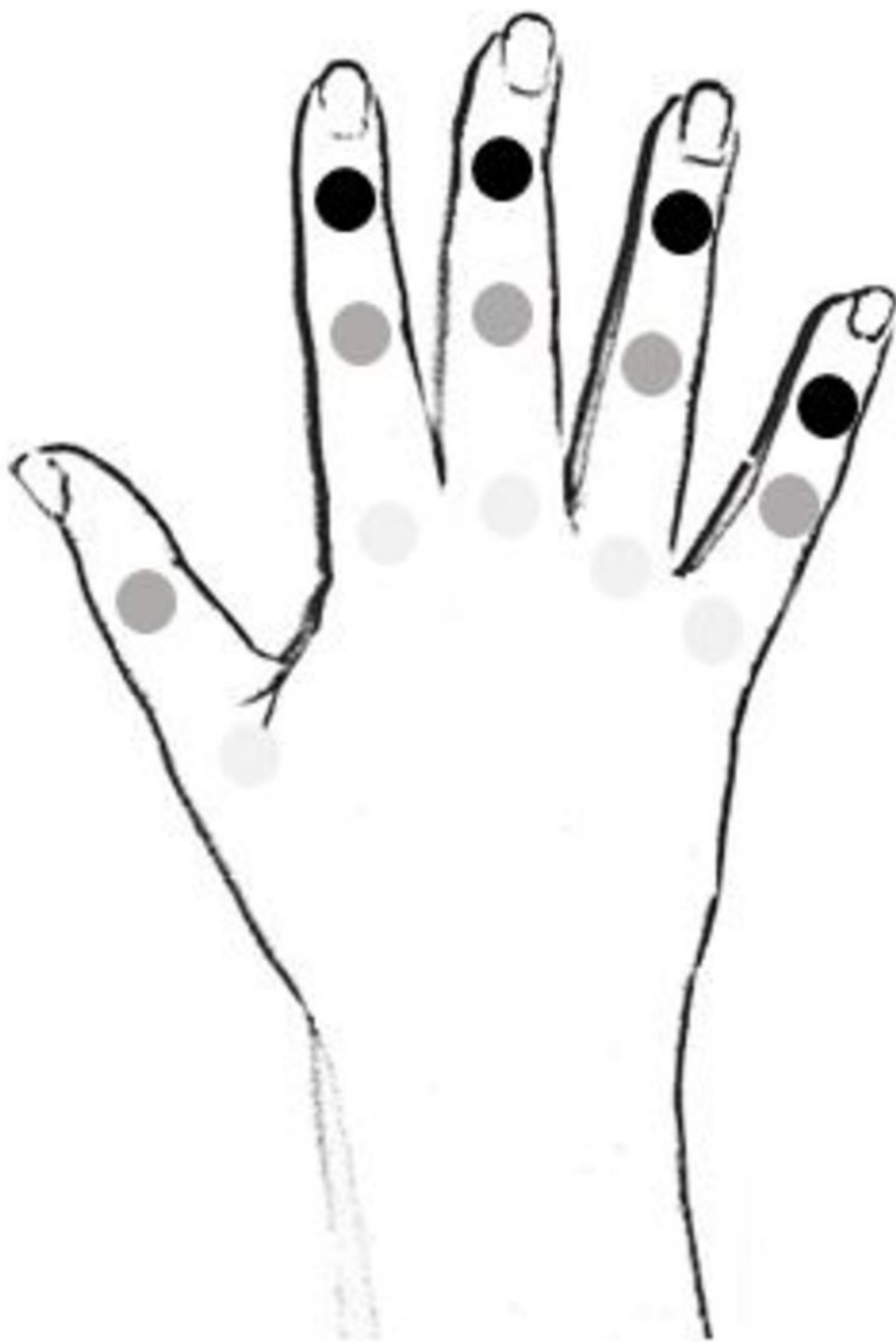**Fig. 9:** Calcium pyrophosphate dihydrate crystal deposition disease. Scheme of involved joints.

© Radiology Department, Coimbra University Hospital - Coimbra/PT



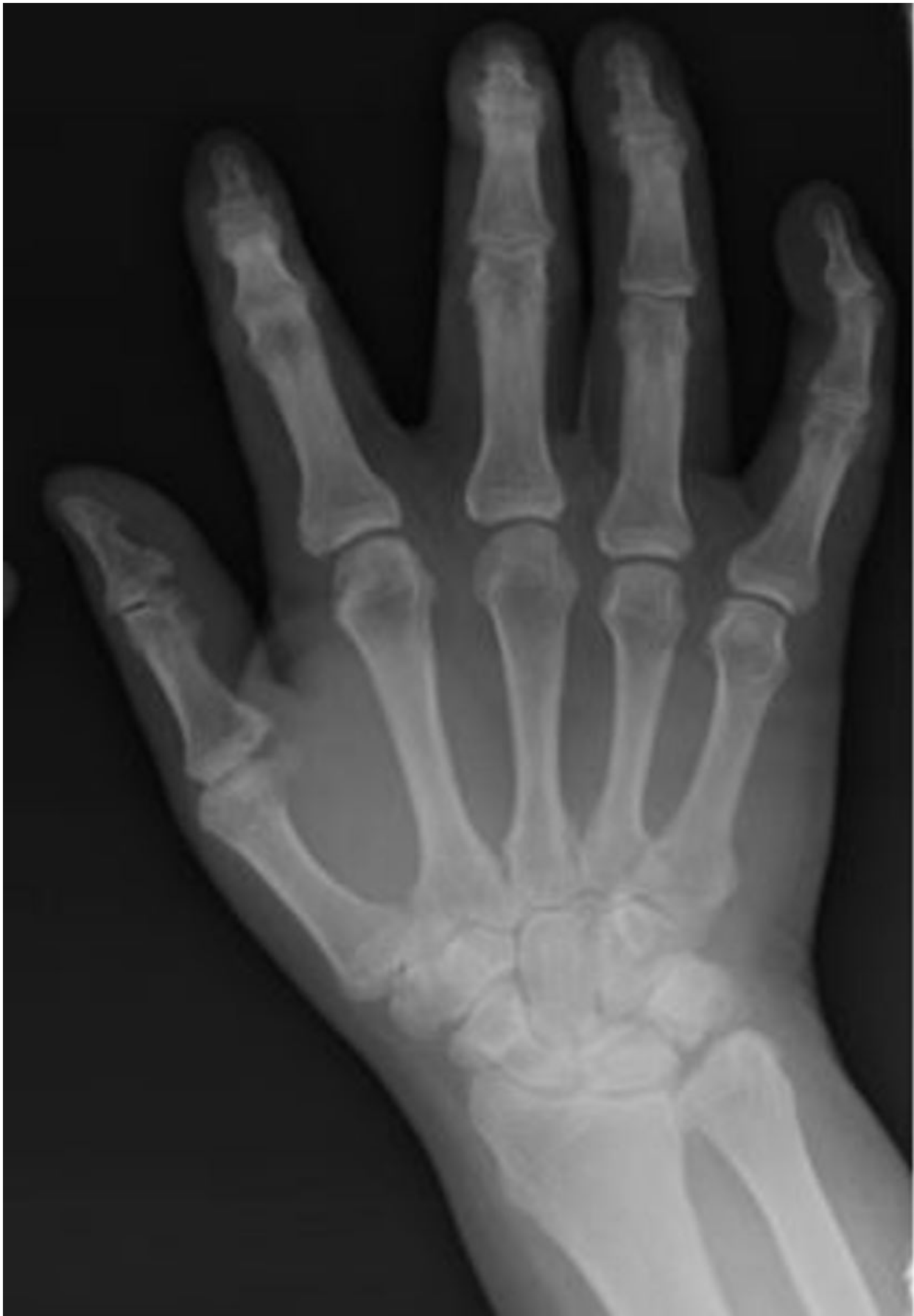**Fig. 10:** Calcium pyrophosphate dihydrate crystal deposition disease. PA radiographic view with small crystal deposition in second MCP and wrist joints.

© Radiology Department, Coimbra University Hospital - Coimbra/PT



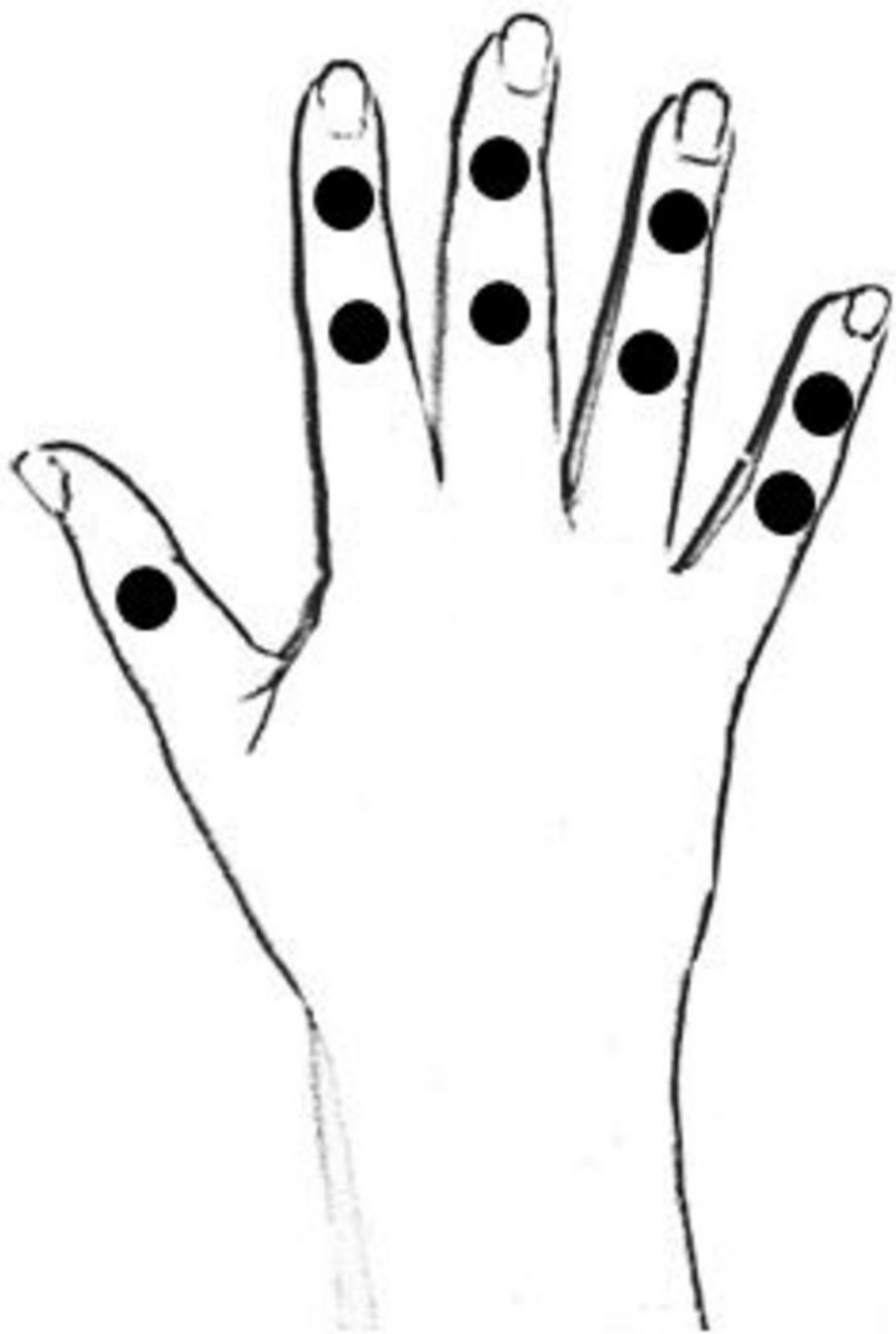**Fig. 11:** Psoriatic arthritis. Scheme of involved joints.

© Radiology Department, Coimbra University Hospital - Coimbra/PT



**Fig. 12:** Psoriatic arthritis. PA radiographic view with changes in DIP and PIP joints.

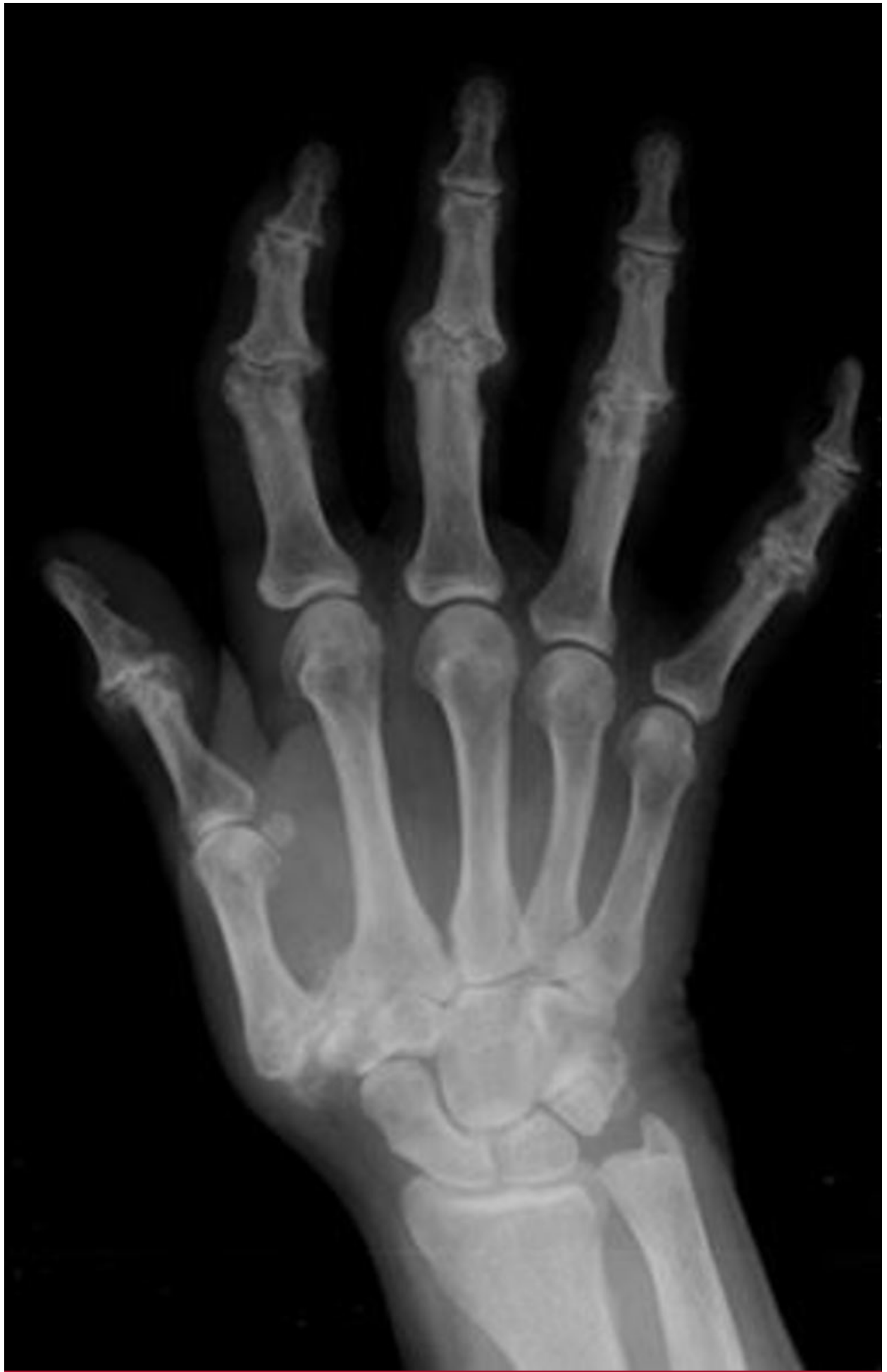© Radiology Department, Coimbra University Hospital - Coimbra/PT



**Fig. 13:** Erosive osteoarthritis. Scheme of involved joints.

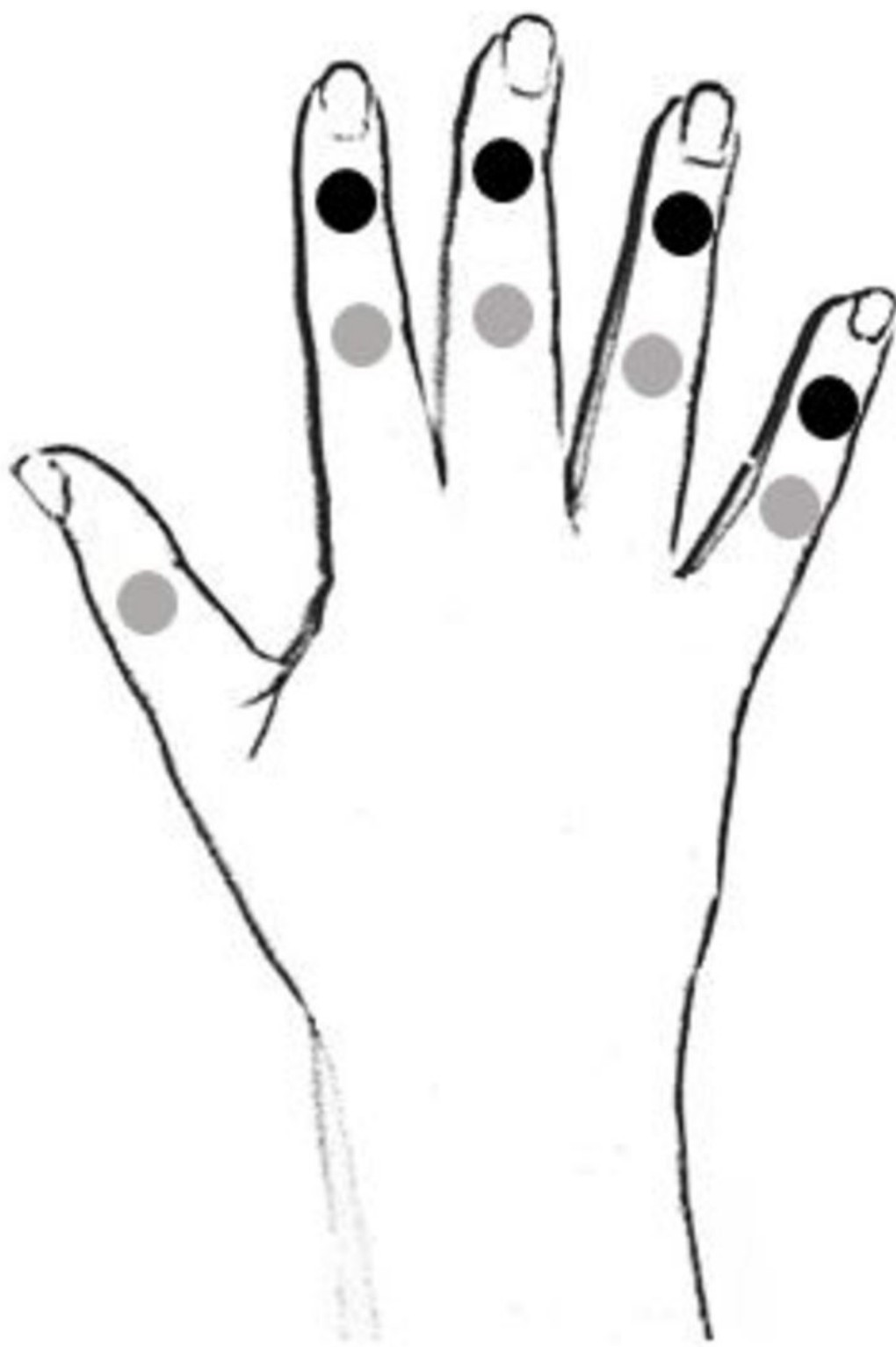© Radiology Department, Coimbra University Hospital - Coimbra/PT





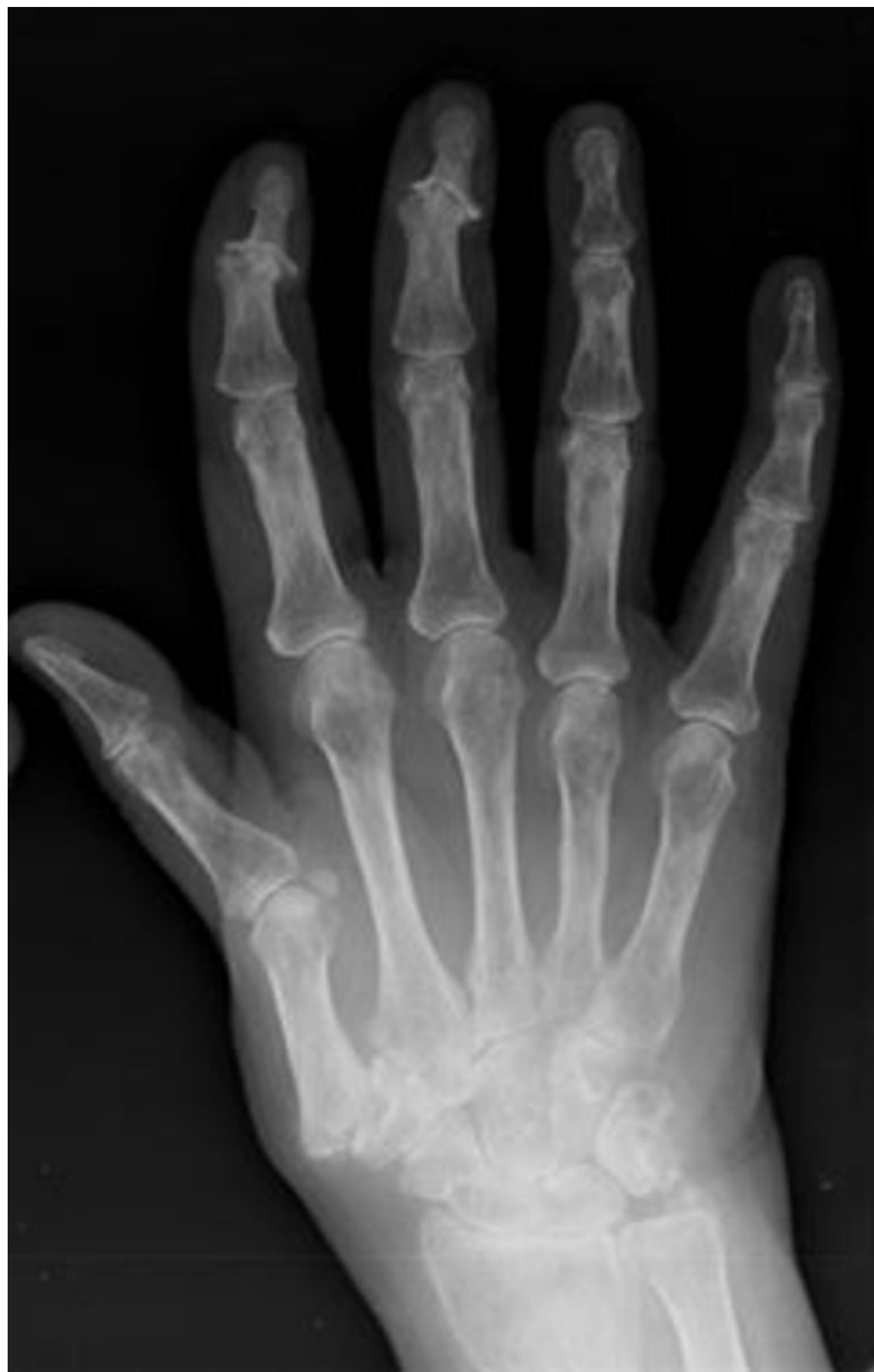**Fig. 14:** Erosive osteoarthritis. PA radiographic view with changes in DIP and PIP joints.

© Radiology Department, Coimbra University Hospital - Coimbra/PT



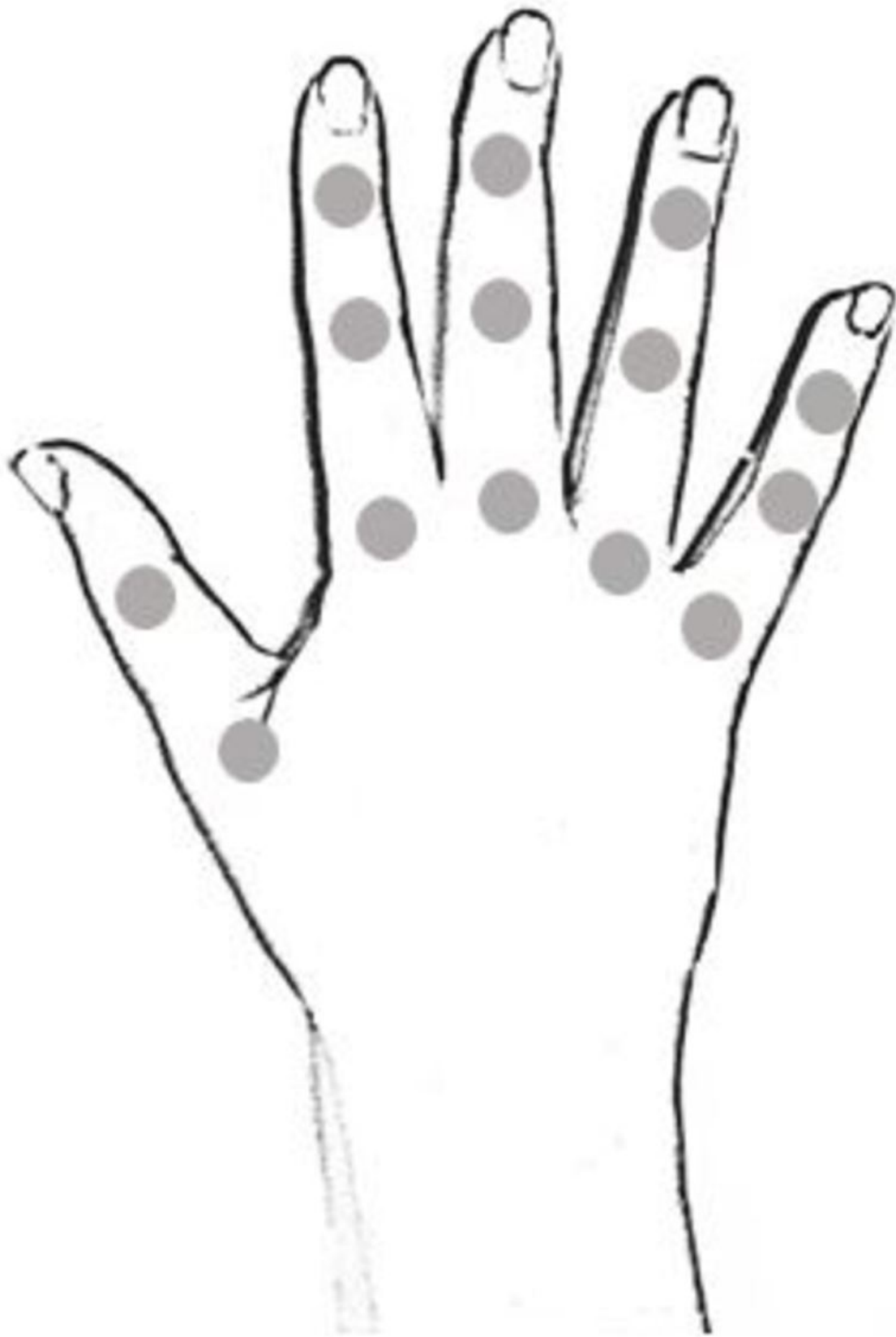**Fig. 15:** Scleroderma and polymyositis. 8.1. Scheme of involved joints.

© Radiology Department, Coimbra University Hospital - Coimbra/PT



**Fig. 16:** PA radiographic view of a patient with scleroderma that shows changes in DIP and PIP joints.

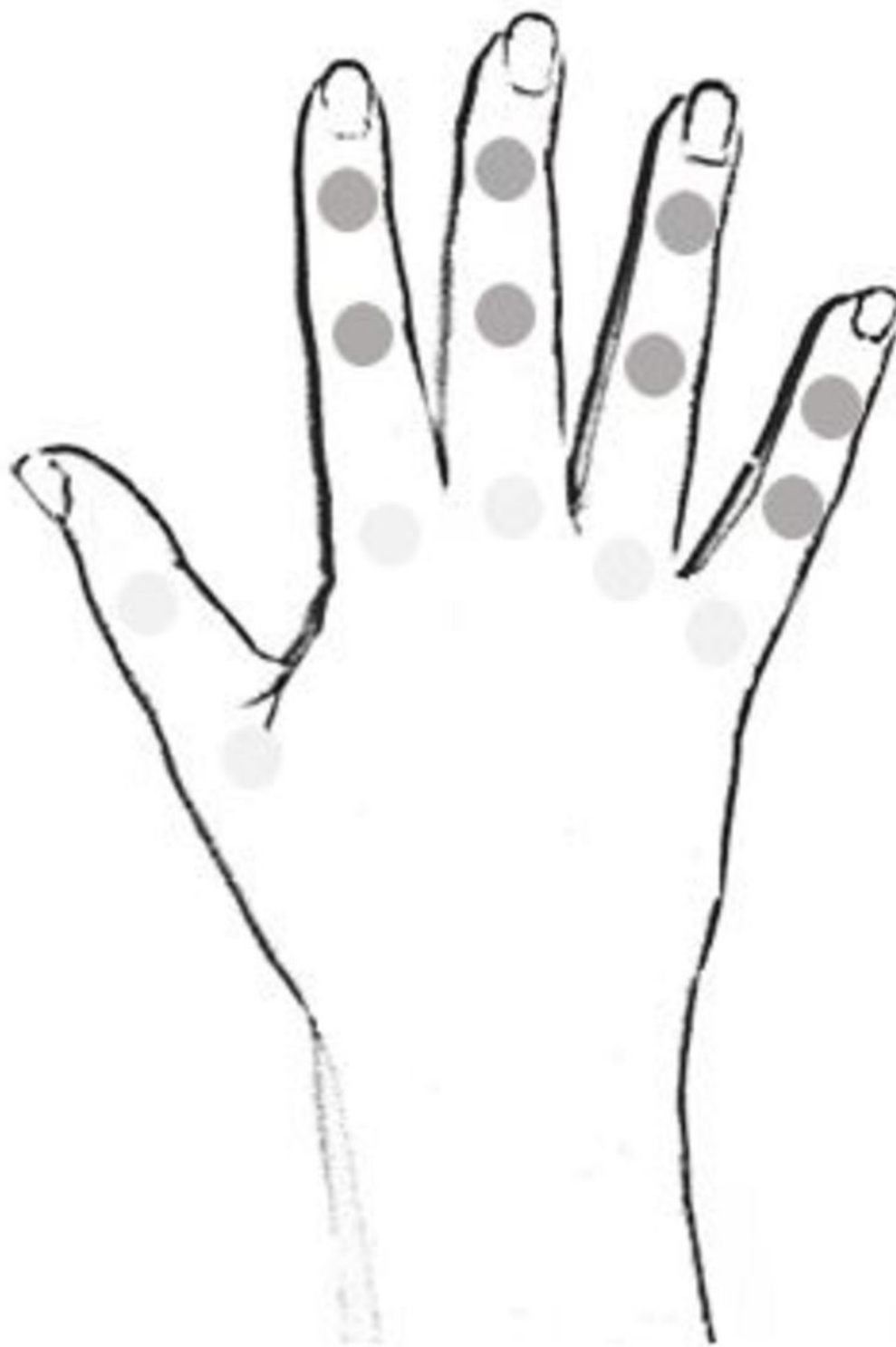© Radiology Department, Coimbra University Hospital - Coimbra/PT



**Fig. 17:** Ankylosing spondylitis. Scheme of involved joints.

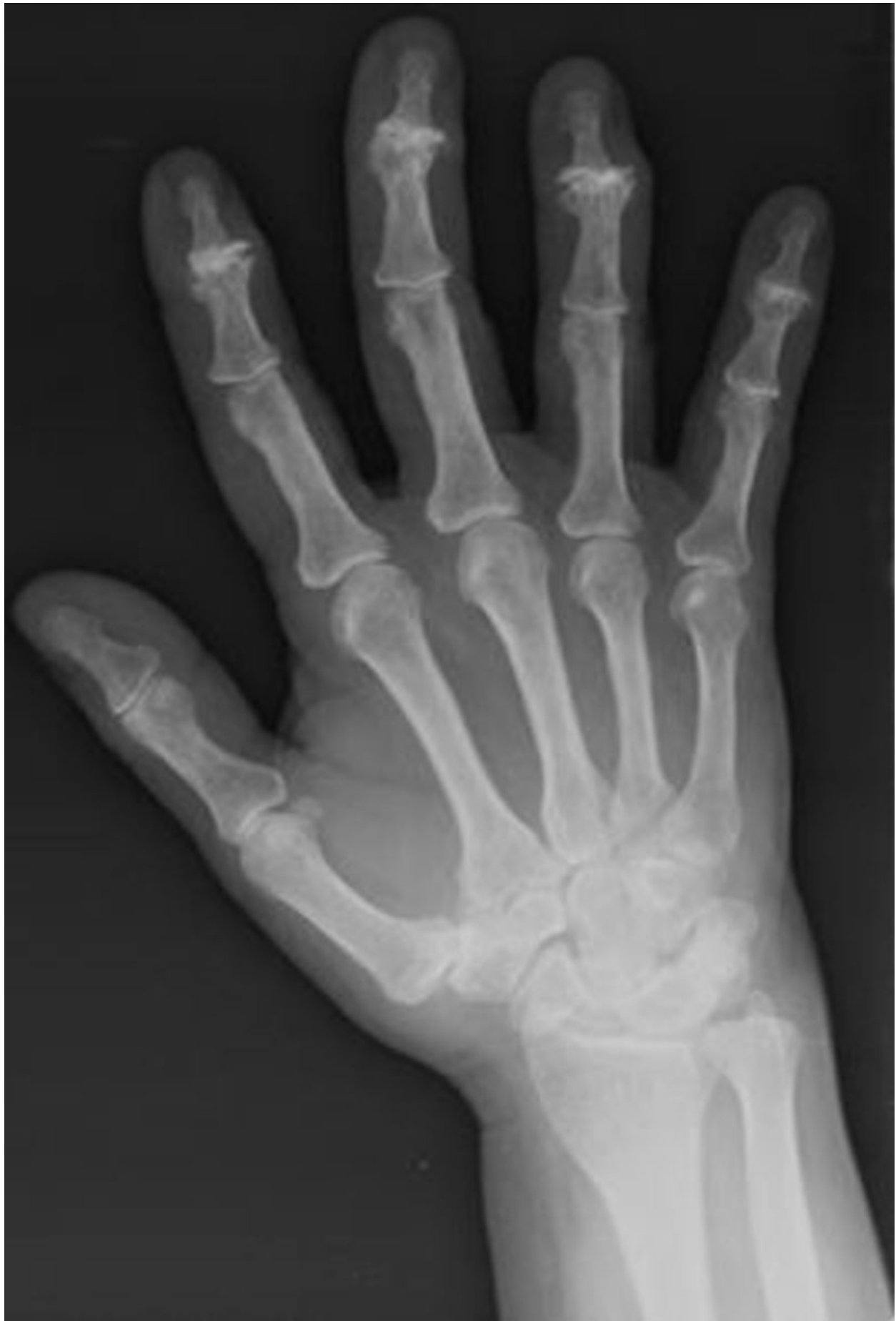© Radiology Department, Coimbra University Hospital - Coimbra/PT





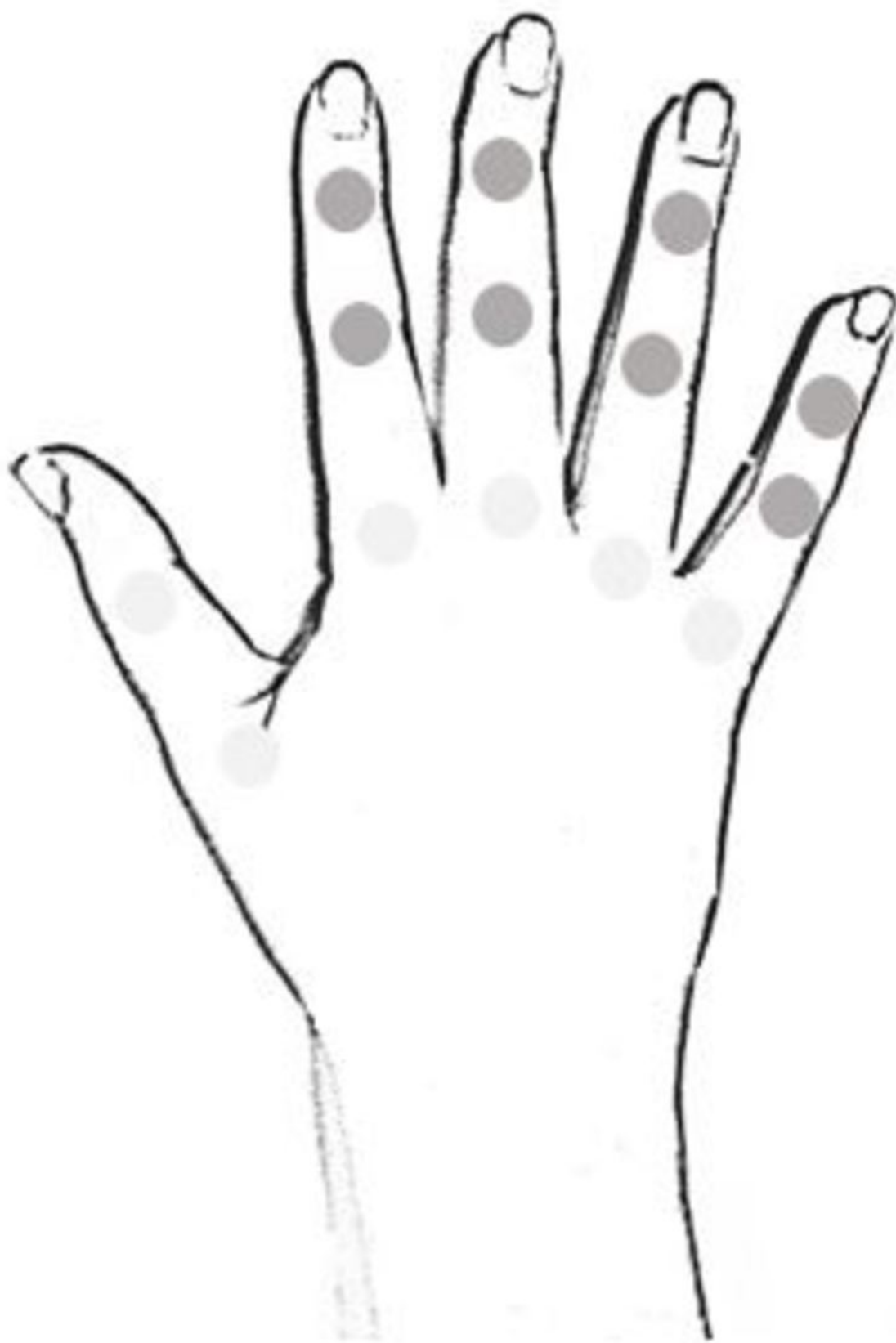**Fig. 18:** Degenerative joint disease and inflammatory osteoarthritis. Scheme of involved joints.





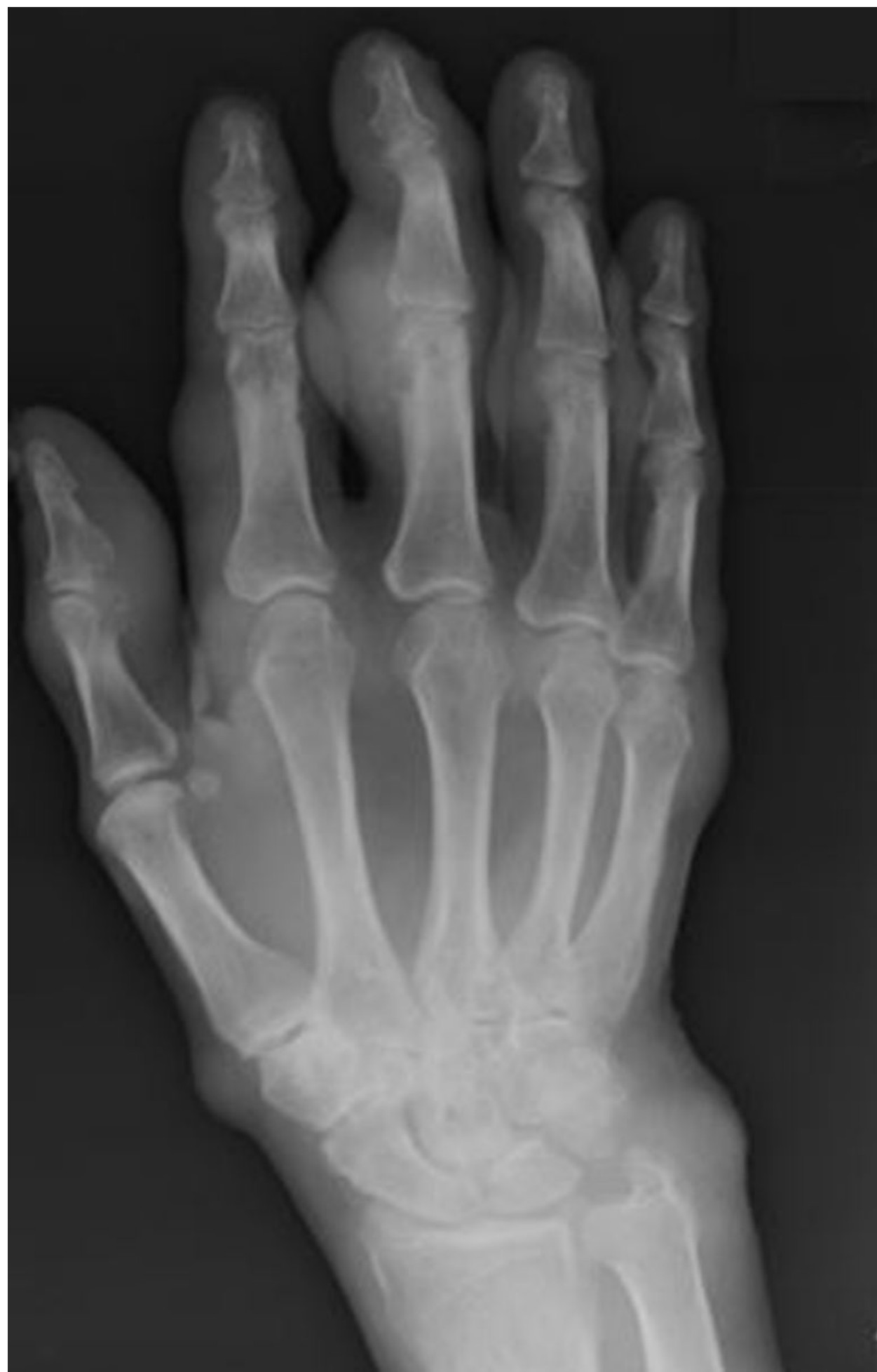**Fig. 19:** Degenerative joint disease and inflammatory osteoarthritis. PA radiographic view with severe arthritis in PIP joints and slight changes in DIP and MCP joints.

© Radiology Department, Coimbra University Hospital - Coimbra/PT



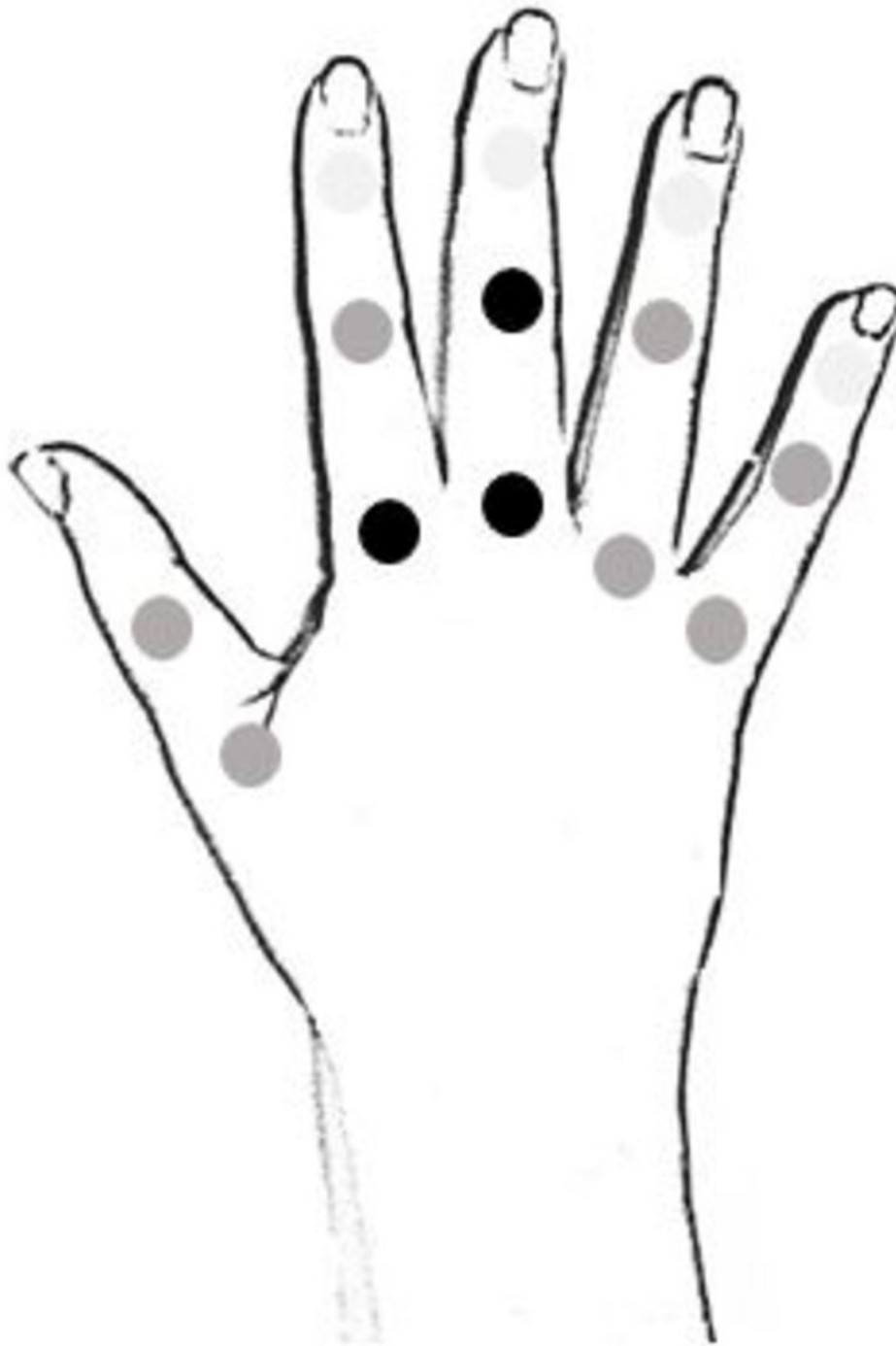
**Fig. 20:** Gouty arthritis. Scheme of involved joints.

© Radiology Department, Coimbra University Hospital - Coimbra/PT



**Fig. 21:** Gouty arthritis. PA radiographic view with changes in all hand joints.

© Radiology Department, Coimbra University Hospital - Coimbra/PT



**Fig. 3:** Rheumatoid arthritis. Scheme of involved joints.

© Radiology Department, Coimbra University Hospital - Coimbra/PT



## Conclusion

The hand diseases have a relatively regular pattern of distribution, allowing the systematization of target areas for each pathology. This in turn may contribute to yield a more focused differential diagnosis.

## Personal information

## References

1. Helms, C. A. Fundamental of skeletal radiology. 4th edition. Mosby Elsevier. Philadelphia, 2014.
2. Jacobson, J. A. et al, Radiographic Evaluation of Arthritis: Inflammatory Conditions, Radiology: Volume 248: Number 2-August 2008
3. Manaster, B. J. et al, The Requisites: Musculoskeletal Imaging. 3rd edition Mosby Elsevier. Philadelphia, 2007.
4. Resnick, D. L., et al. Bone and joint imaging. 3rd edition. Mosby Elsevier. Philadelphia, 2005.